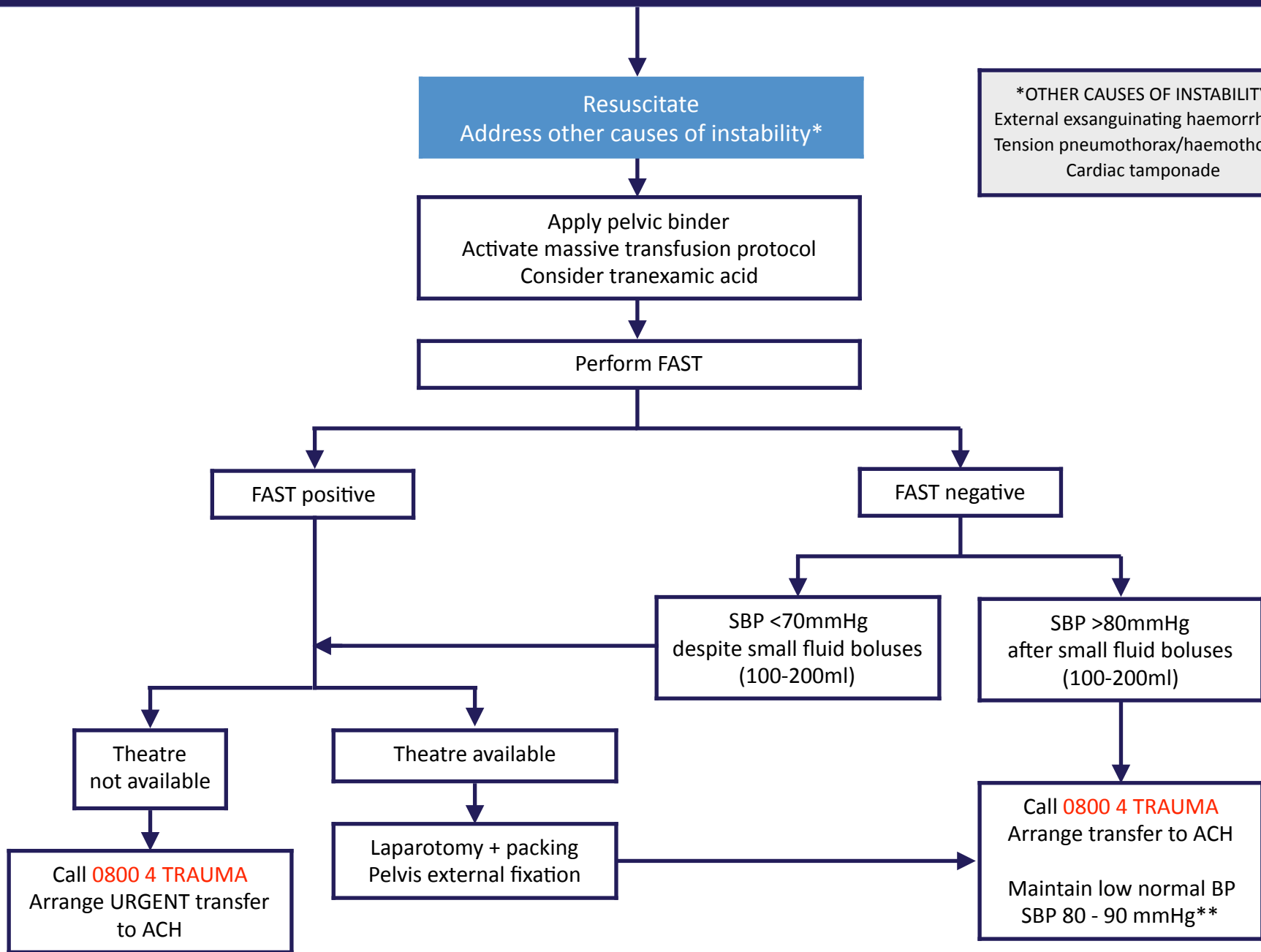


Management of the haemodynamically UNSTABLE patient with a fractured pelvis

ANGIOGRAPHY NOT AVAILABLE



*OTHER CAUSES OF INSTABILITY
External exsanguinating haemorrhage
Tension pneumothorax/haemothorax
Cardiac tamponade

**If suspect TBI, consider maintaining SBP >90mmHg. Caution in the elderly